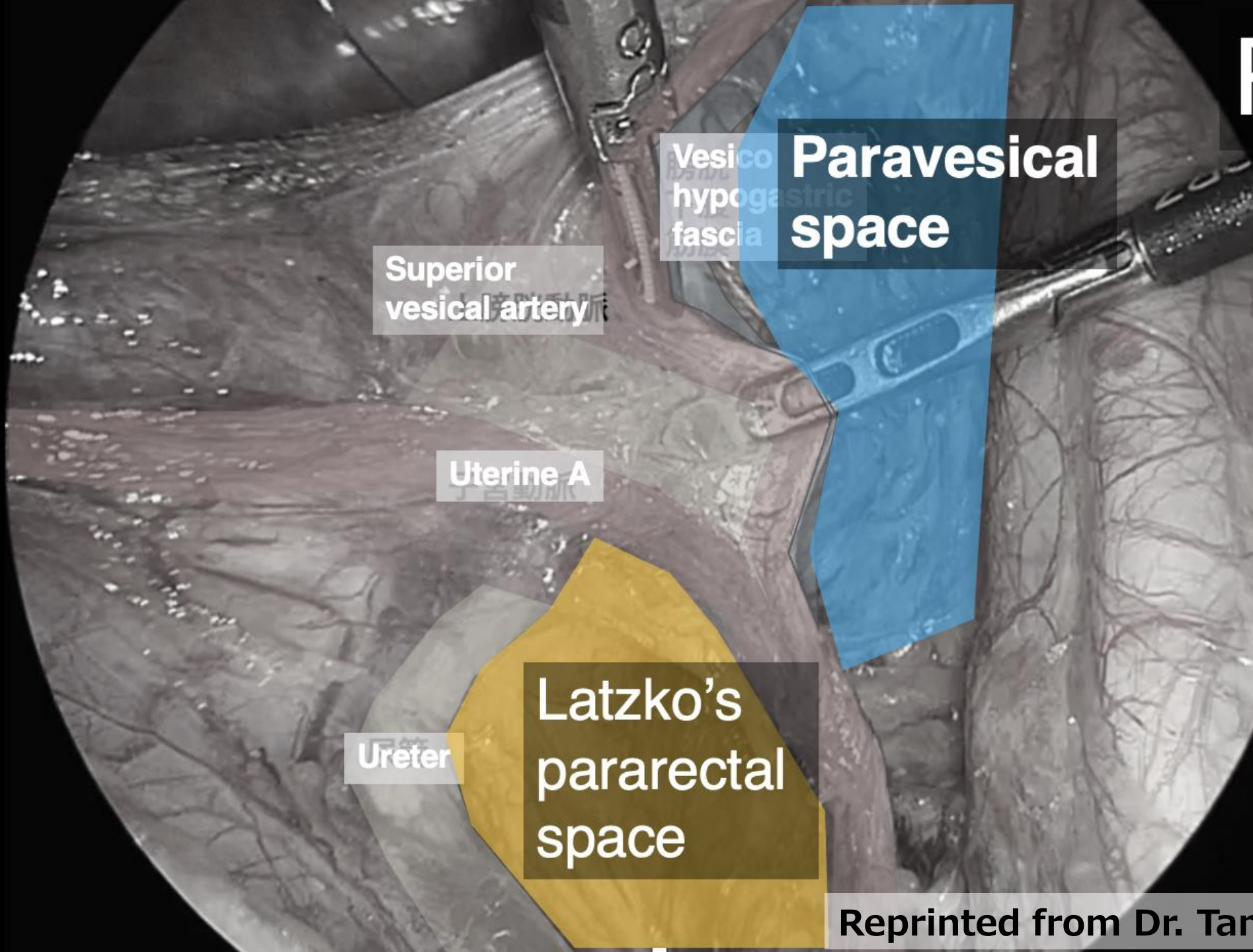


Discussion

Surgical Procedure for Laparoscopic Pelvic Lymphadenectomy

It's become common practice to expand the paravesical space, pararectal space, and the space between the iliac vessels and the psoas major muscle before removing pelvic lymph nodes.
How about in your country?

Right



Vesico
hypogastric
fascia

**Paravesical
space**

**Superior
vesical artery**

Uterine A

Ureter

**Latzko's
pararectal
space**

Discussion

Surgical Procedure for Laparoscopic Pelvic Lymphadenectomy

It's become common practice to expand the paravesical space, pararectal space, and the space between the iliac vessels and the psoas major muscle before removing pelvic lymph nodes.
How about in your country?

Surgical Technique for Nerve-Sparing Radical Hysterectomy

What do you consider important for nerve preservation?
Specifically, what precautions do you take when handling the posterior layer of the uterosacral ligament?

Right

