

Vulvar Intraepithelial Neoplasia -Optimizing The Outcome

Amita Suneja, MD

Sr consultant, Masonic Williams Clinic

Ex Director Professor & HOD

UCMS & GTBH

DELHI, INDIA

VIN

- Premalignant lesion involving *squamous epithelium*
- Relatively rare: 0.5 – 1.5/1,00,000 women
- Incidence is rising, involving young women
- Underdiagnosed & undertreated
- Preventable
- Recent concepts are evolving

ISSVD Classification Squamous Intraepithelial Lesions of Vulva

1994

- **Analogy to CIN**
- VIN 1
- VIN 2
- VIN 3
- ⑩ No TZ
- ⑩ HPV lesions are different
- ⑩ VIN 1 NEVER progresses to cancer

2004

- ⑩ Condyloma, HPV effect is not VIN
- uVIN (usual type)
 - Warty
 - Basaloid
 - Mixed
- dVIN (differentiated)

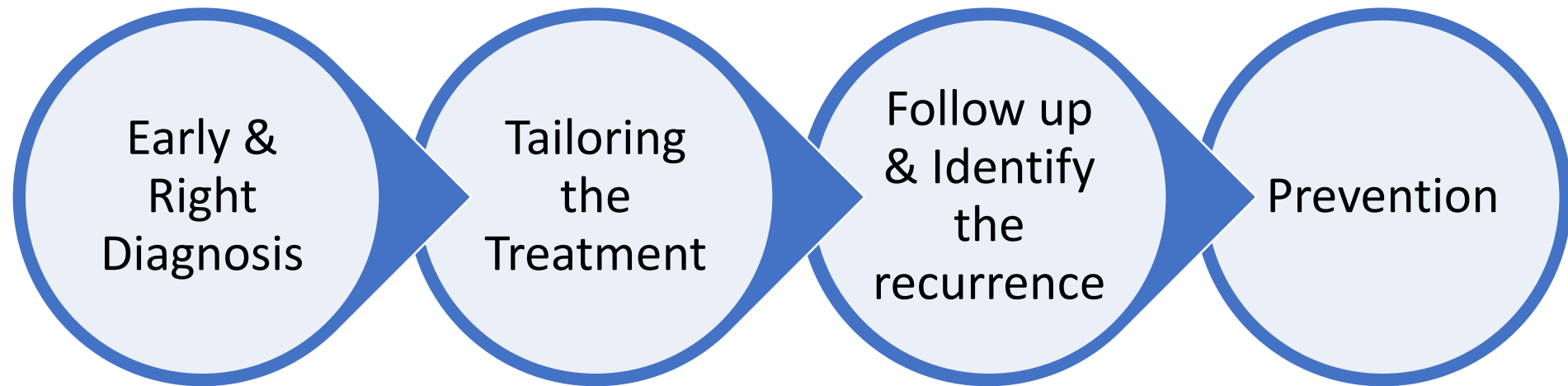
2015

- LSIL
 - vulvar LSIL
 - Flat condyloma
 - HPV effect
- HSIL - uVIN
- dVIN

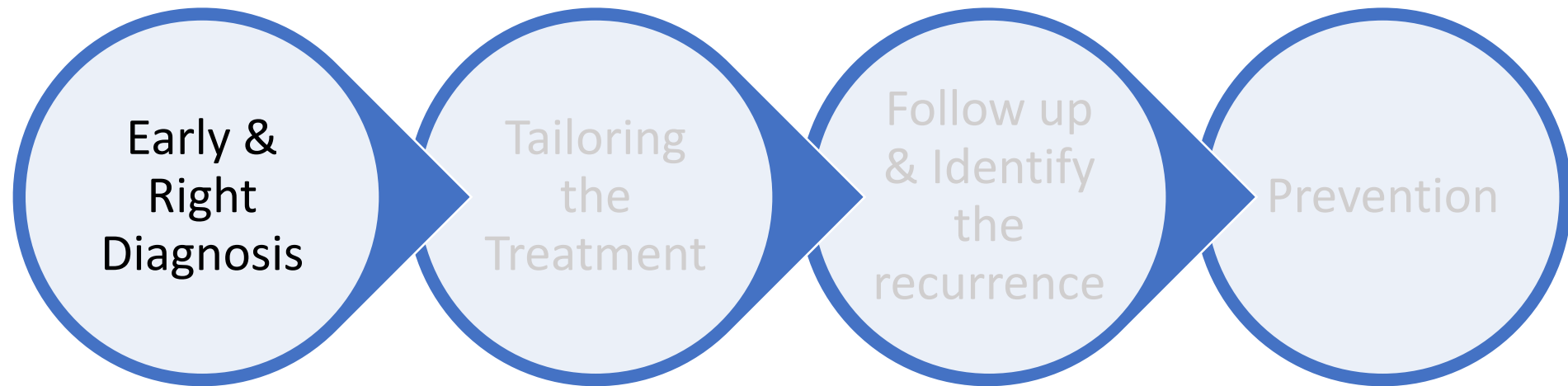
2020 WHO Terminology

- HPV-associated squamous intraepithelial lesions
 - LSIL
 - HSIL (uVIN, VHSIL)
- HPV-independent VIN
 - differentiated VIN (dVIN)
 - differentiated exophytic vulvar intraepithelial lesion (DEVIL)
 - vulvar acanthosis with altered differentiation (VAAD)

Vulvar Intraepithelial Neoplasia -Optimizing The Outcome



Vulvar Intraepithelial Neoplasia - Optimizing The Outcome





HSIL (uVIN, VSIL)

- Usual type
- 90%
- Associated with HPV
- Younger age group
- Malignant potential
 - 5-10% - 4 years

dVIN


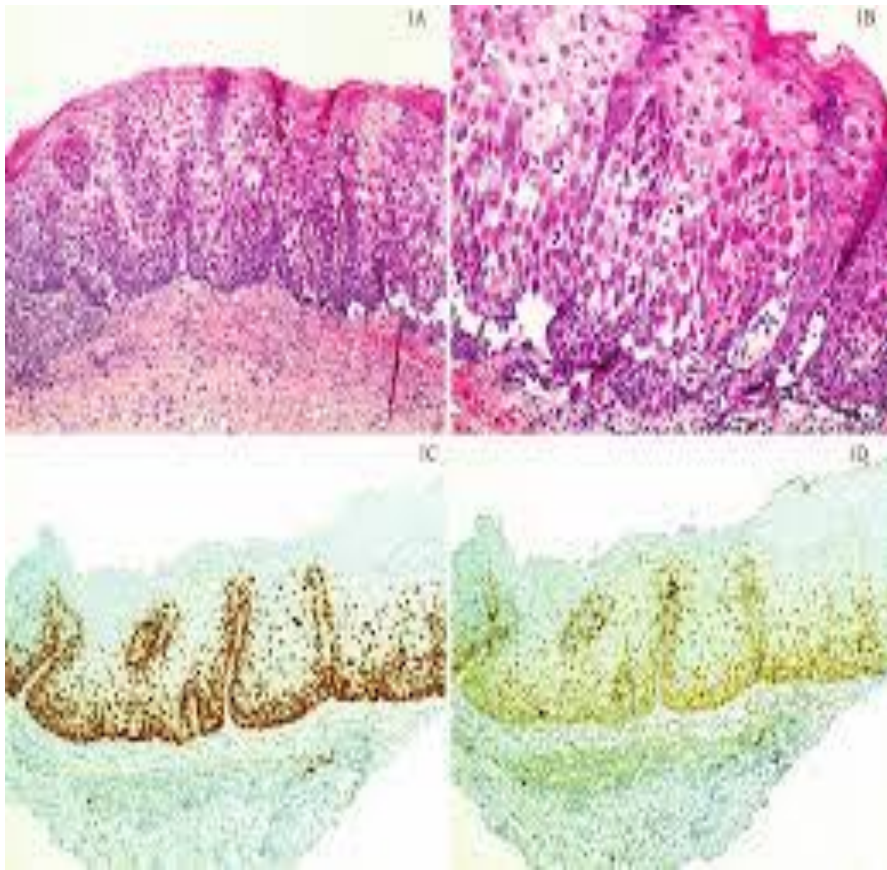


- Worse type
- 10%
- With Vulvar dermatosis
- Older women
- 30% - 2years

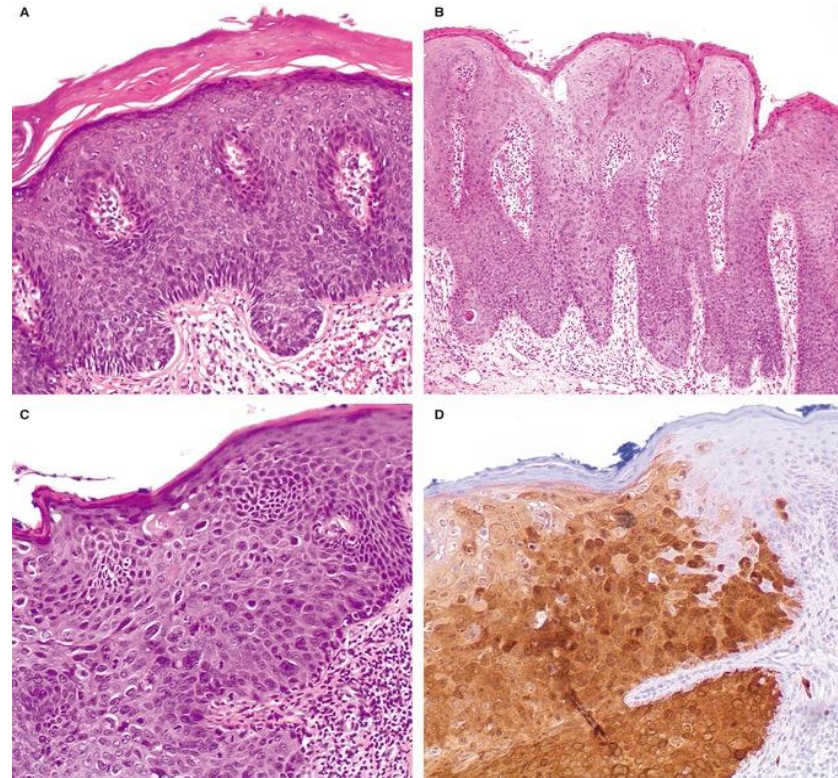
50% are asymptomatic

- Multifocal lesions
- Different size, shape, colour
- Macules, plaques, pigmentations, condyloma

- Itching, White plaques
- distortion of anatomy
- Clitoral involvement
- Kraurosis



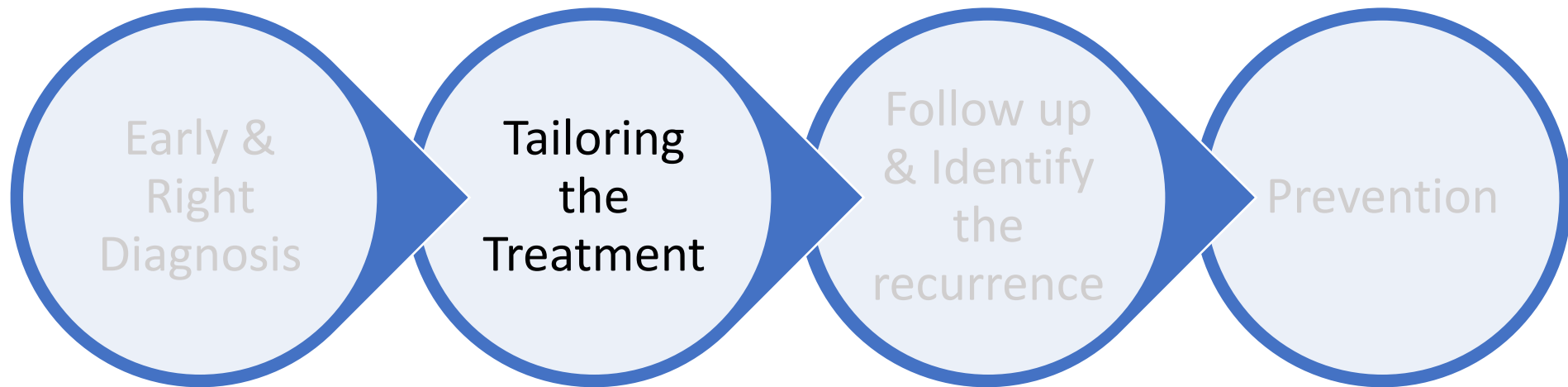
dVIN with P53 & Ki67 positivity



uVIN with P16 staining



Vulvar Intraepithelial Neoplasia -Optimizing The Outcome



Objectives of Treatment

- 1.To prevent progression to invasive carcinoma
- 2.Cure or alleviate symptoms
- 3.Avoid relapses
- 4.To preserve vulvar anatomy and functionality

Treatment is tailored depending on

- **histopathology**
- **size**
- **location and**
- **Type of lesion (multifocal or unifocal)**

Treatment Modalities

HSIL- VIN usual type

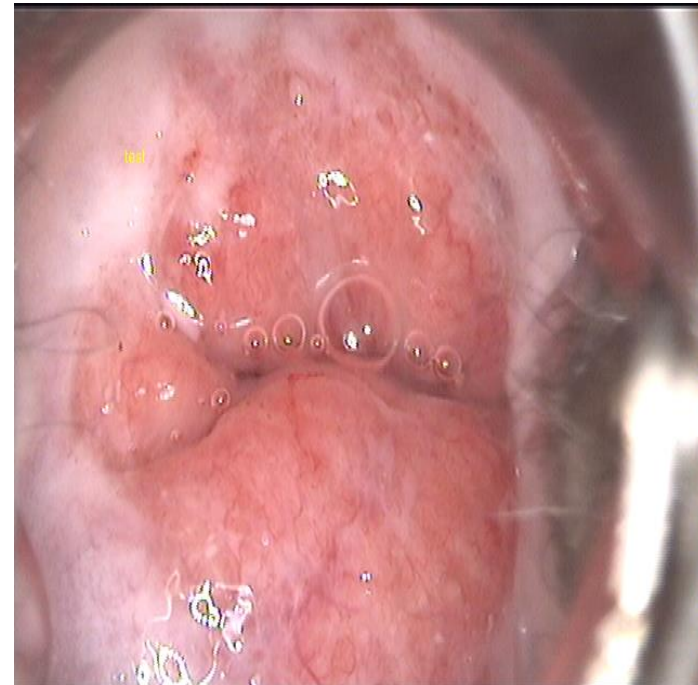
- Surgery is the best option
- No suspicion of occult cancer
 - LASER
 - Topical treatment
 - Imiquimod 5% thrice a week for 16-20 weeks
 - 1% cidofovir gel
 - 5 FU
 - Photodynamic light therapy
 - CUSA

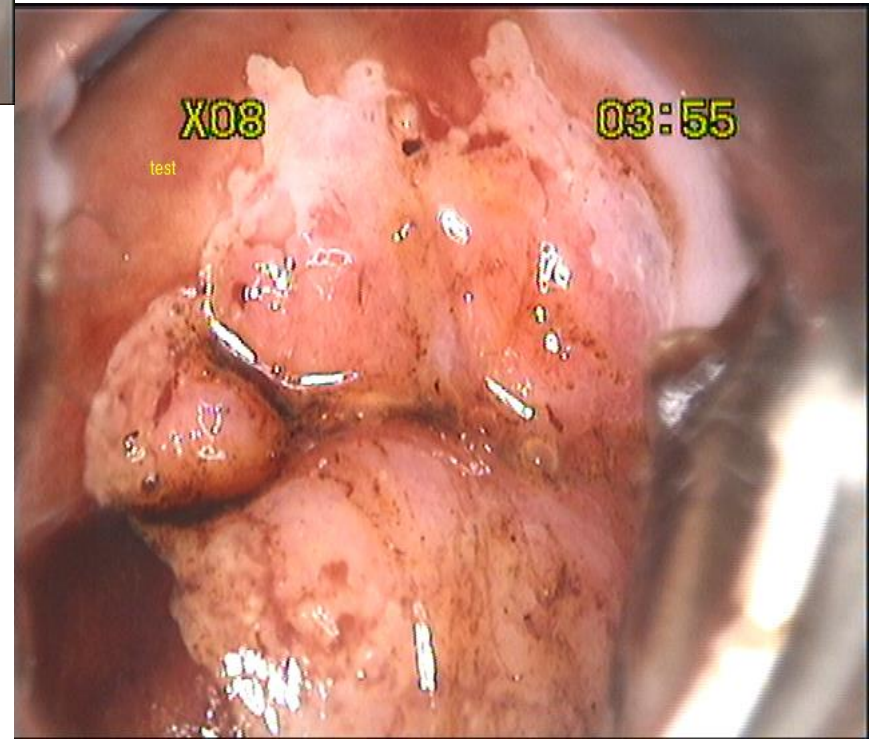
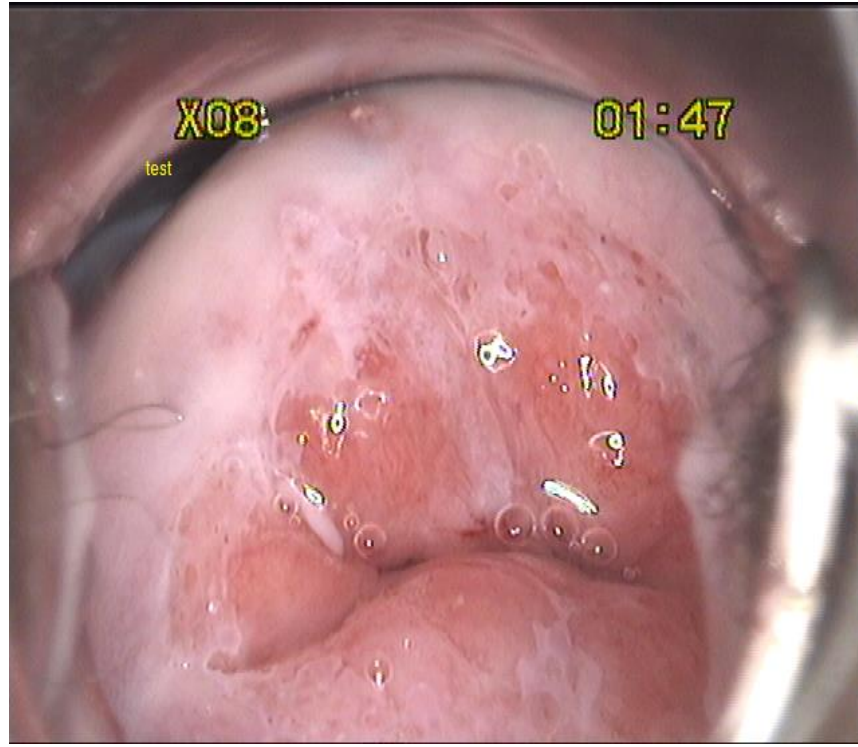
VIN Differentiated

- Surgery is the only option
- Wide local excision/skinning vulvectomy
- Margin: 0.5-1cm all around
 - Tailor it near urethra, clitoris & anus
- Depth: 2-3mm

Case 1

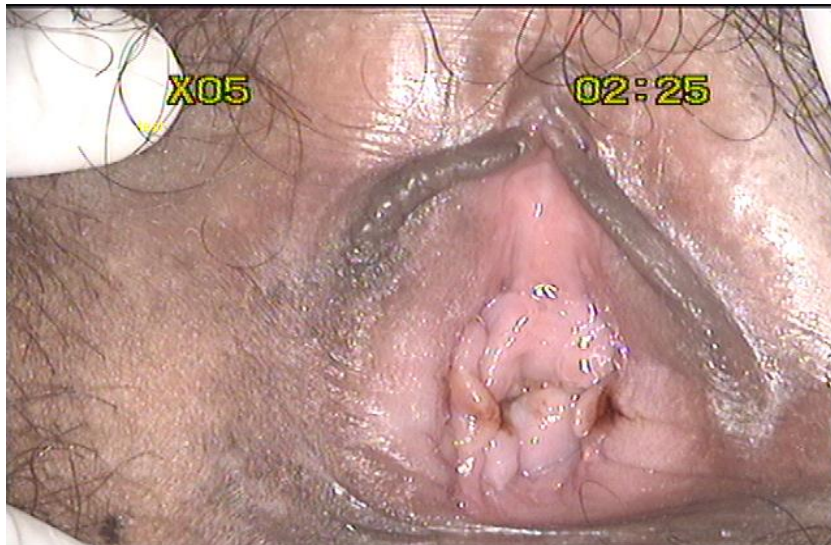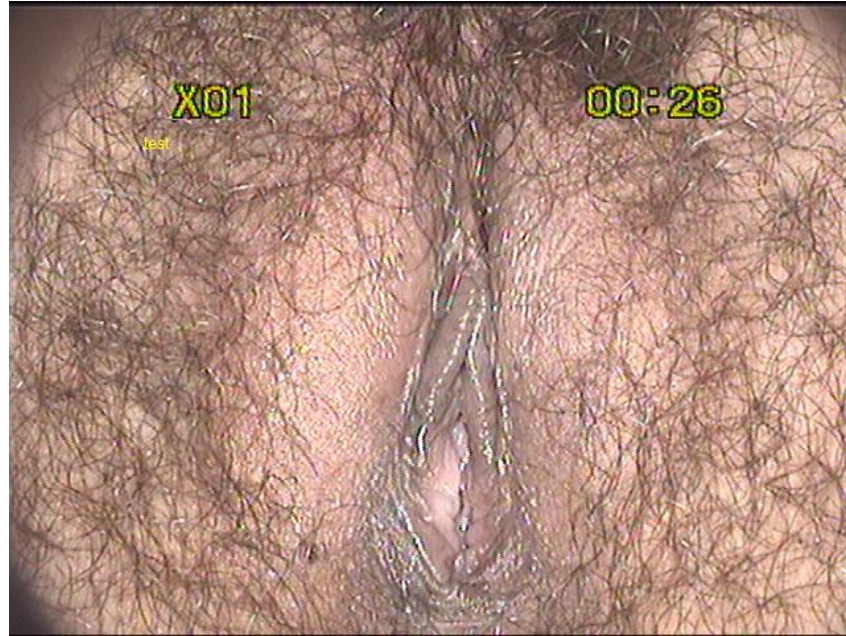- Mrs X, 29 yrs, P2
- Vulvar itching – 6 months
- T/t-
 - clotrimazole 1 Vg pessaries, ointment
 - Fluconazole/tinidazole
 - KIT 1 & 2
- Pap smear – NIELM
- Wet smear - normal



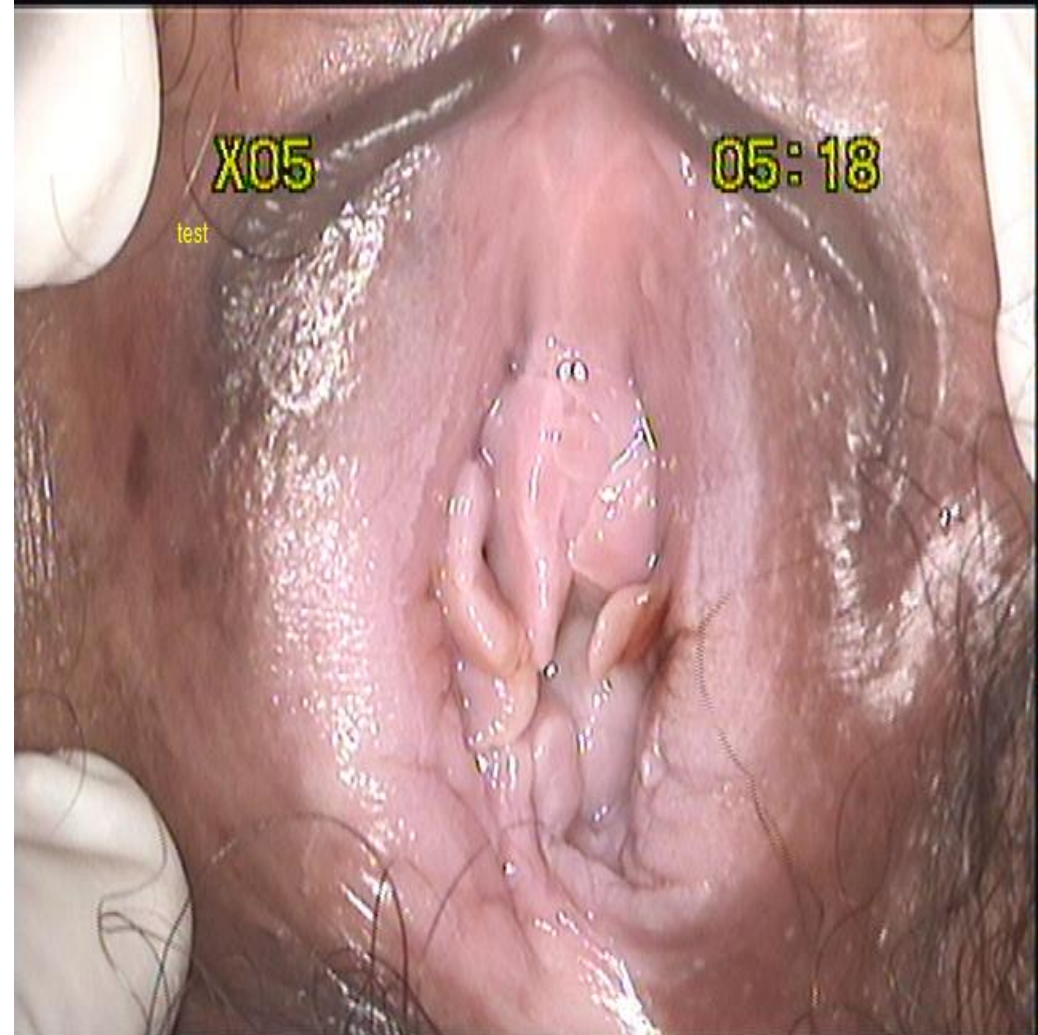

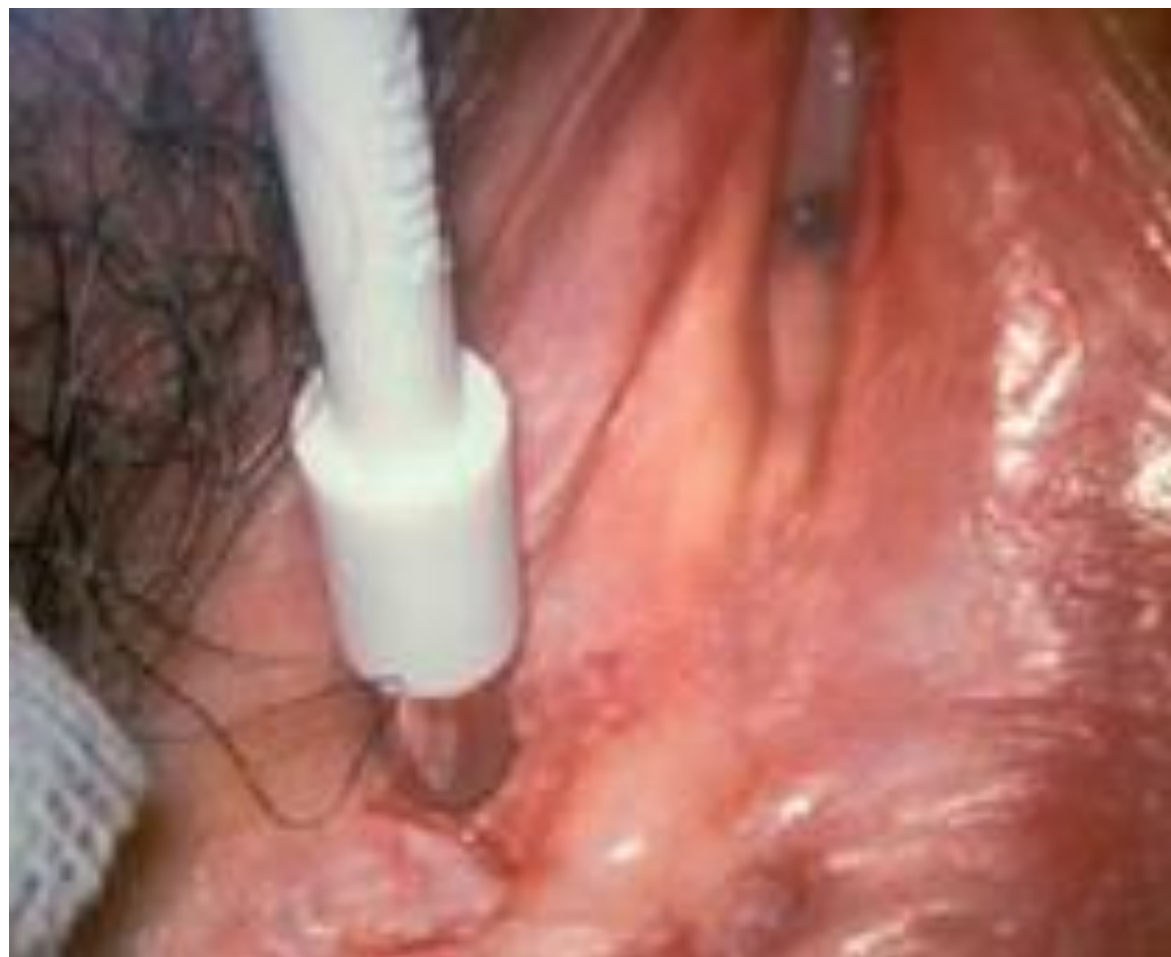Type 1 TZ, Minor grade abnormality of TZ

Gross examination



Vulvoscopy





Vulvar Bx- HPV like changes with HSIL (VIN 2)

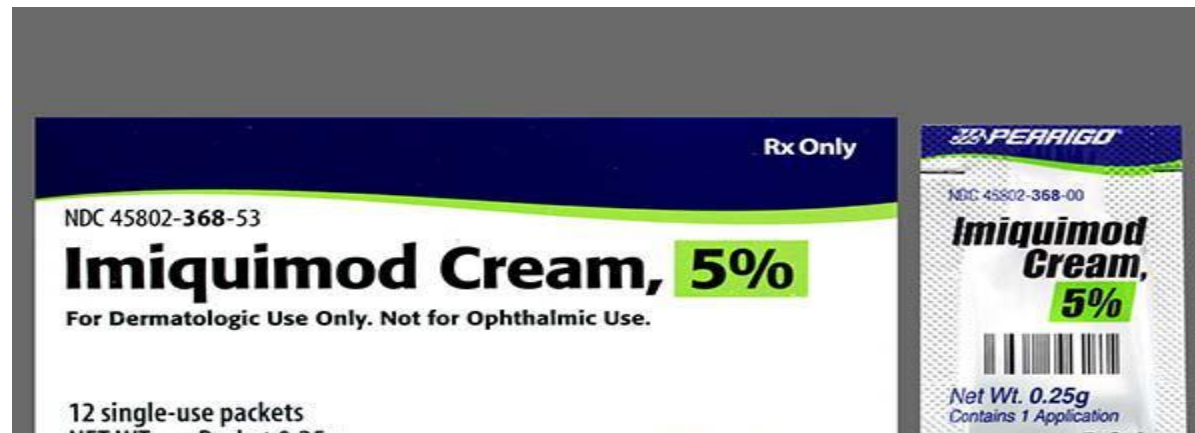
Cx Bx - HPV related changes with HSIL (CIN II)

VHSIL

- 4% of women with SIL may involve cervix, vagina, anus
- Must screen cervix and vagina
- Not enough data to screen all VHSIL with high resolution anoscopy & anal cytology sensitivity is very low
- History should be asked for anal canal symptoms

Treatment ????

- Thermal ablation for CIN II
- VIN
 - Imiquimod 5% for LA 3 days a week
 - Steroid ointment for other 3 days of a week
 - Duration of treatment-14 weeks



Efficacy of imiquimod

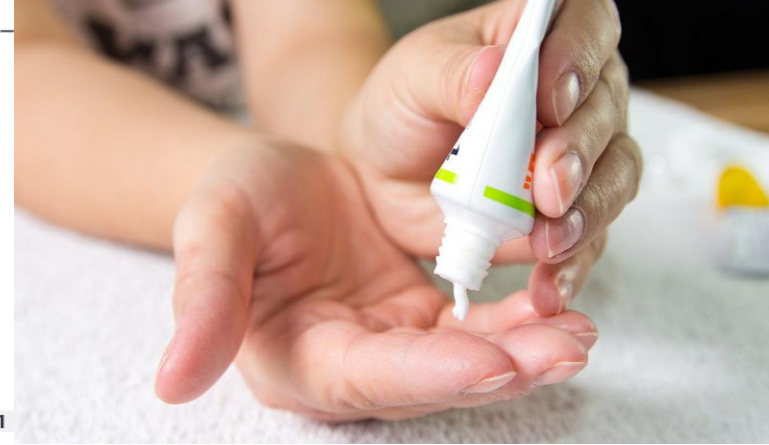	Study design	Response Rate	Follow up	
<i>van Seters M, et al, 2002</i>	Pilot study	CR+ PR - 87%	–	
<i>Mathiesen O, et al 2007</i>	RCT Placebo controlled	CR – 81% vs 0%	–	
<i>van Seters M et al 2008</i>	RCT Placebo controlled 26 patients in each group	RR – 81% vs 0% CR - 35% vs 0% at 20 weeks of therapy	12 months FU of patients – No difference in progression to IC (<1MM) 1/26 VS 2/26 PATIENTS WITH CR WERE DISEASE FREE AT 12 MONTHS FU	

RR - REDUCTION IN LESION SIZE ATLEAST BY 25%

Recurrence rate after IMIQUIMOD – 20-27% at 16-21 months after treatment

Activity, safety, and feasibility of **cidofovir and imiquimod** for treatment of vulval intraepithelial neoplasia (RT³VIN): a multicentre, open-label, randomised, phase 2 trial

Amanda Tristram¹, Christopher N Hurt², Tracie Madden³, Ned Powell¹, Stephen Man⁴, Sam Hibbitts¹, Peter Dutton³, Sadie Jones¹, Andrew J Nordin⁵, Raj Naik⁶, Alison Fiander¹, Gareth Griffiths⁷

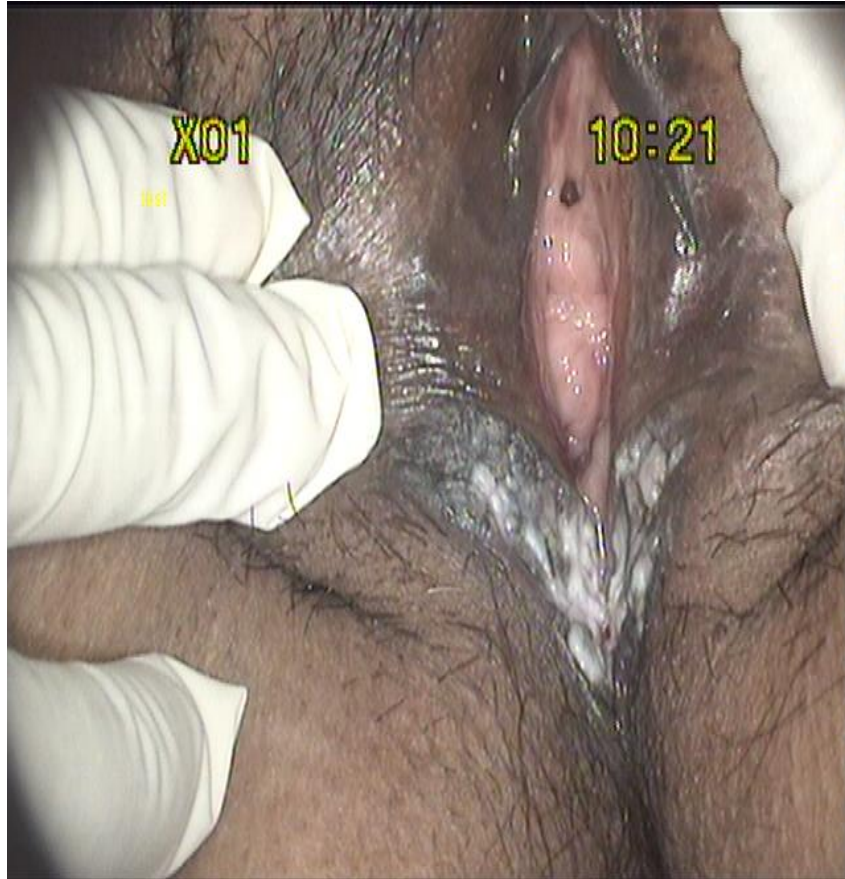

Methods: We recruited female patients (age 16 years or older) from 32 centres to an open-label, randomised, phase 2 trial. Eligibility criteria were biopsy-proven vulval intraepithelial neoplasia grade 3 and at least one lesion that could be measured accurately. We randomly allocated patients to topical treatment with either **1% cidofovir (supplied as a gel in a 10 g tube, to last 6 weeks)** or 5% imiquimod (one 250 mg sachet for every application), to be self-applied three times a week for a maximum of 24 weeks. Randomisation (1:1) was done by stratified minimisation via a central

Interpretation: Cidofovir and imiquimod were active, safe, and feasible for treatment of vulval intraepithelial neoplasia and warrant further investigation in a phase 3 setting. Both drugs are effective alternatives to surgery for female patients with vulval intraepithelial neoplasia after exclusion of occult invasive disease.

HPV E2 DNA Methylation is biomarker for prediction of good response to cidofovir

CASE 2 – uVIN/ VHSIL



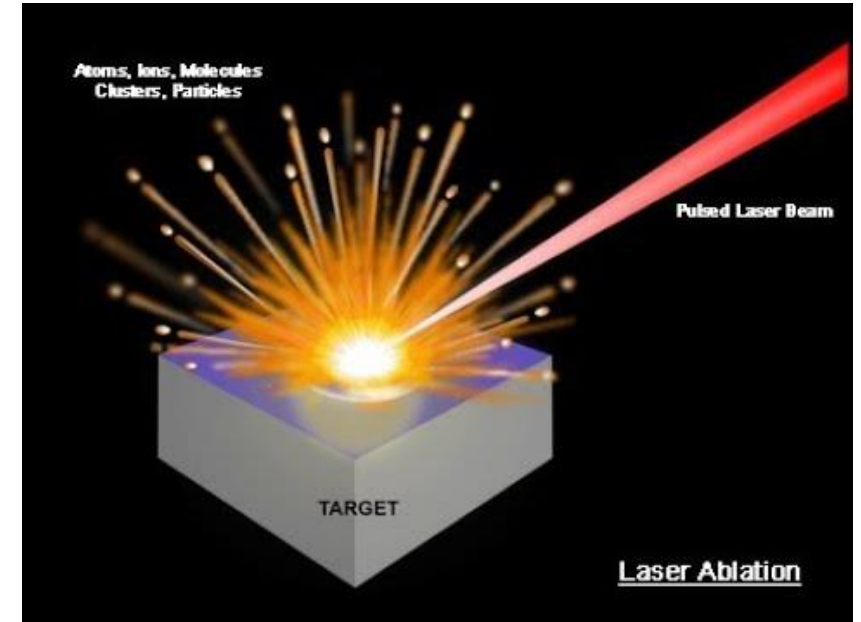
- Wide local excision
- Occult cancer 3%
- Recurrence is less as compared to conservative means

LASER ABLATION

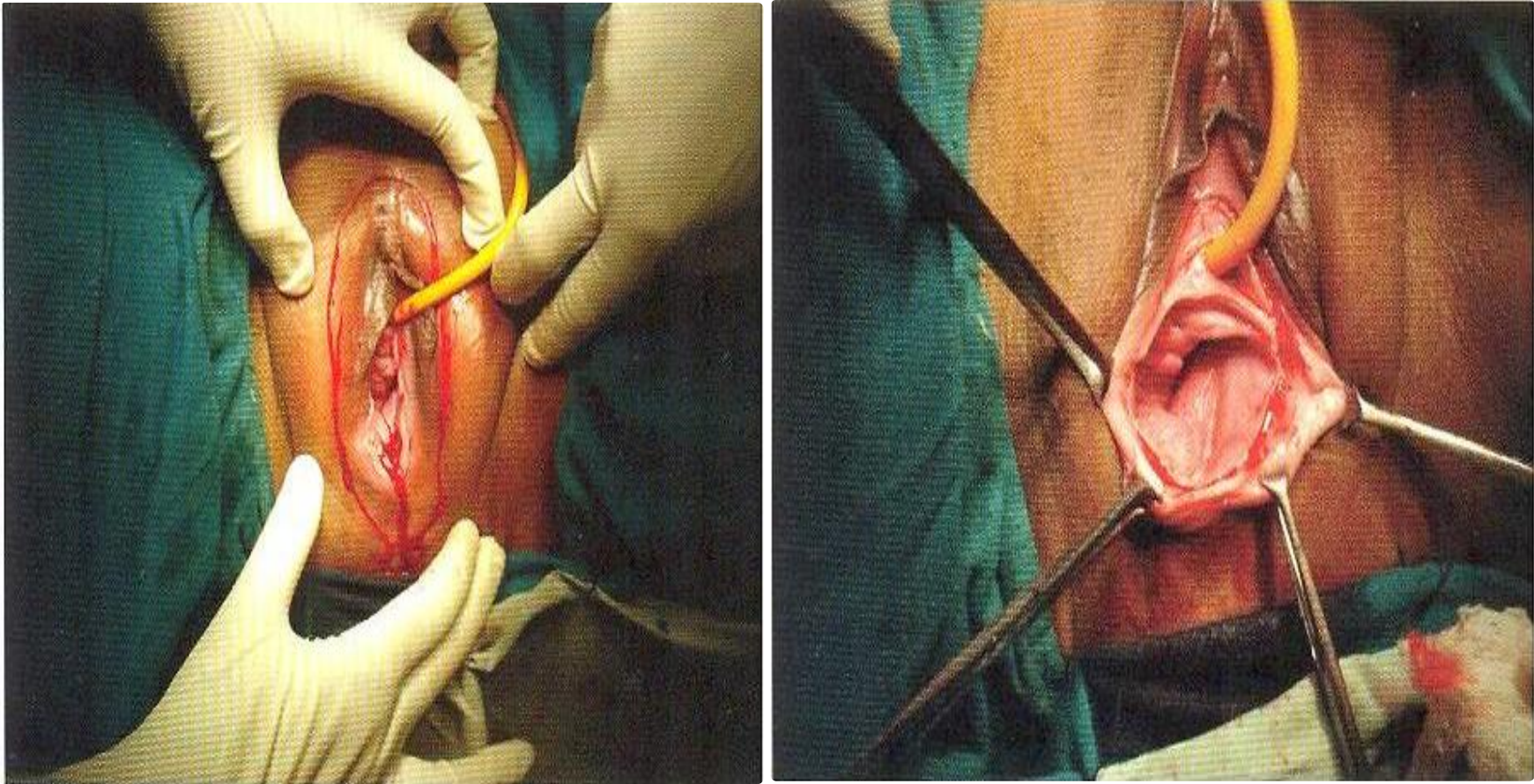
- No suspicion of invasion
- Can be used for single, multifocal or confluent lesions
- Delineate the lesions by vulvoscopy
- PD 750-1250/cm²
- Ablate 0.5-1 cm around the lesion
- Depth
 - Upto 2mm of dermis non hairy area
 - Upto 2-4mm in hair bearing area

Surgical excision is preferred in

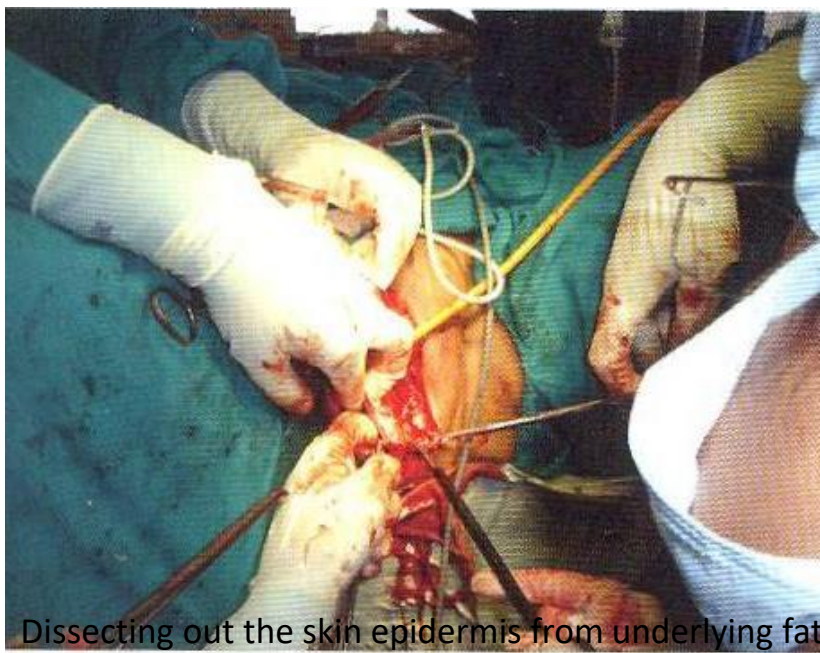
- Large lesions,
- hair bearing area,
- invasion can not be ruled out.



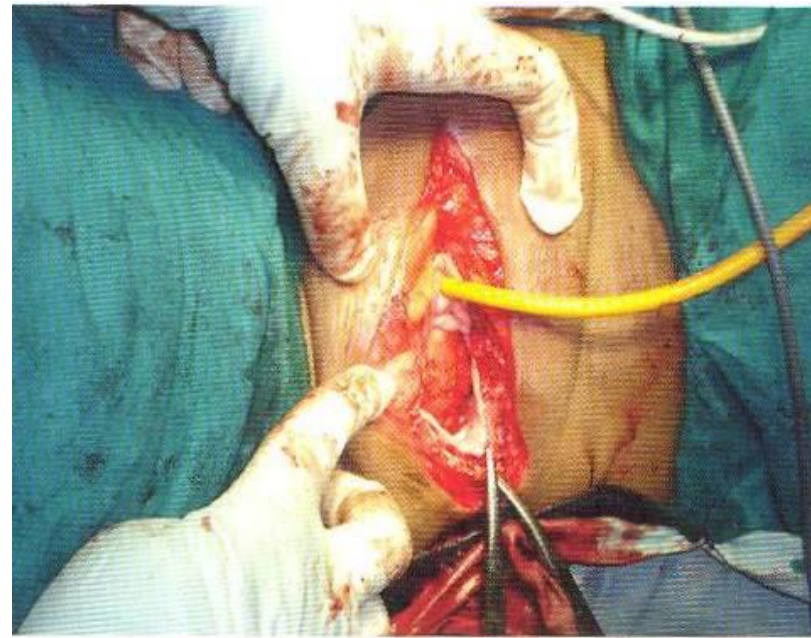
CASE 3- Partial Skinning Vulvectomy



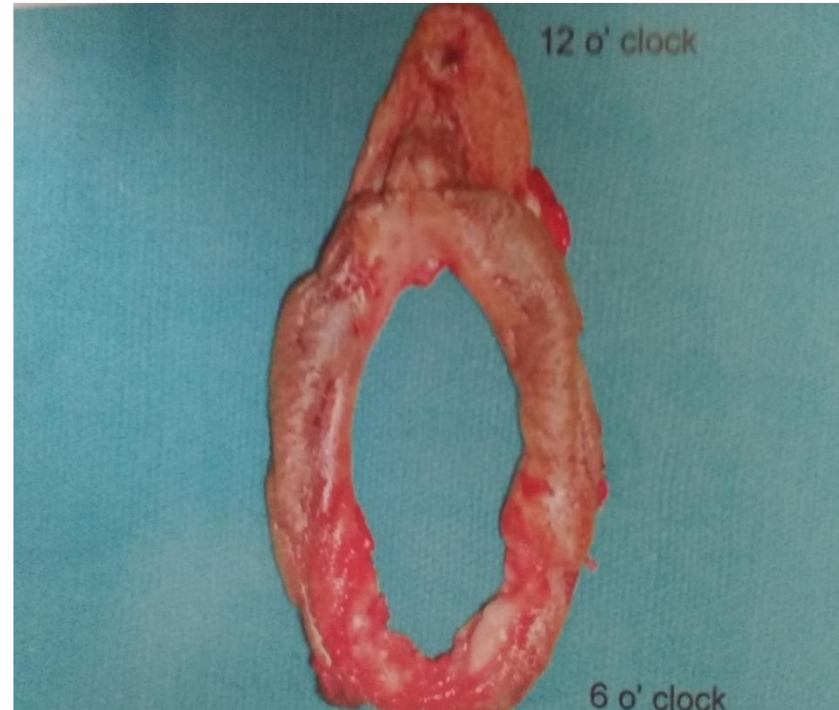
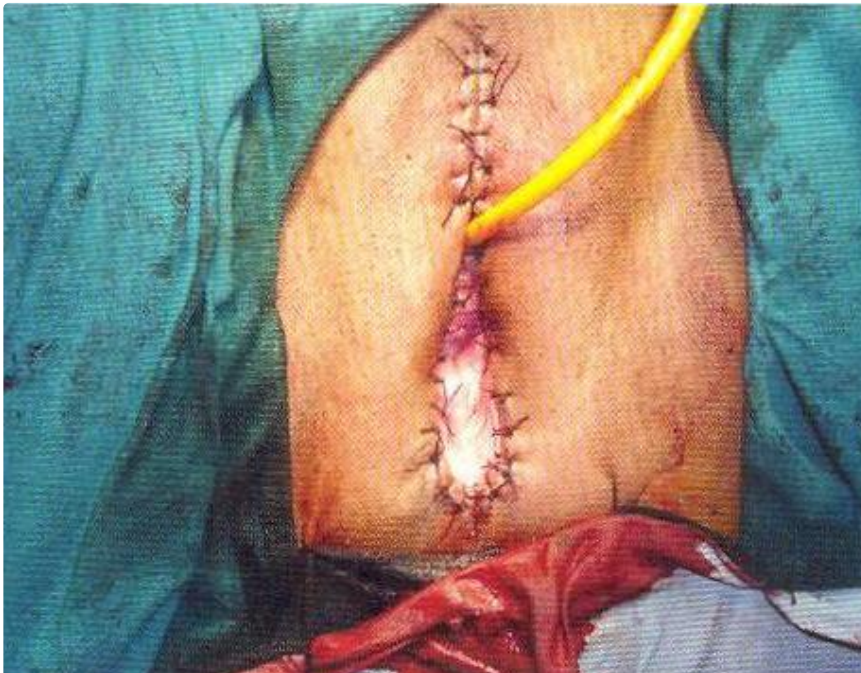
Defining the incision line after application of 5% acetic acid



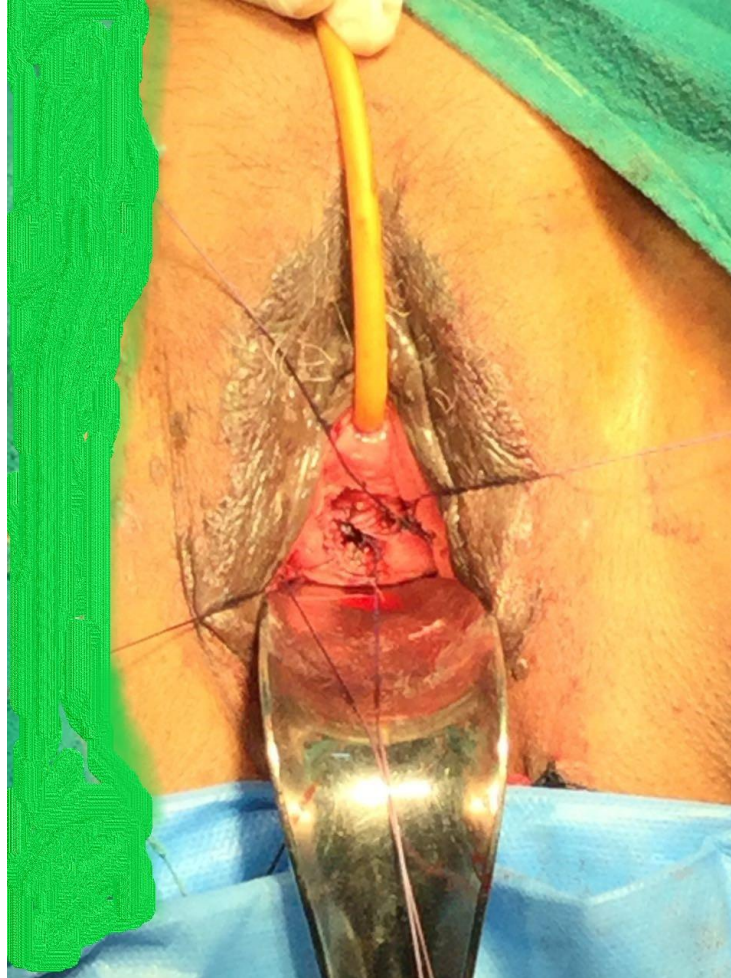
Dissecting out the skin epidermis from underlying fat



Perineum after complete excision

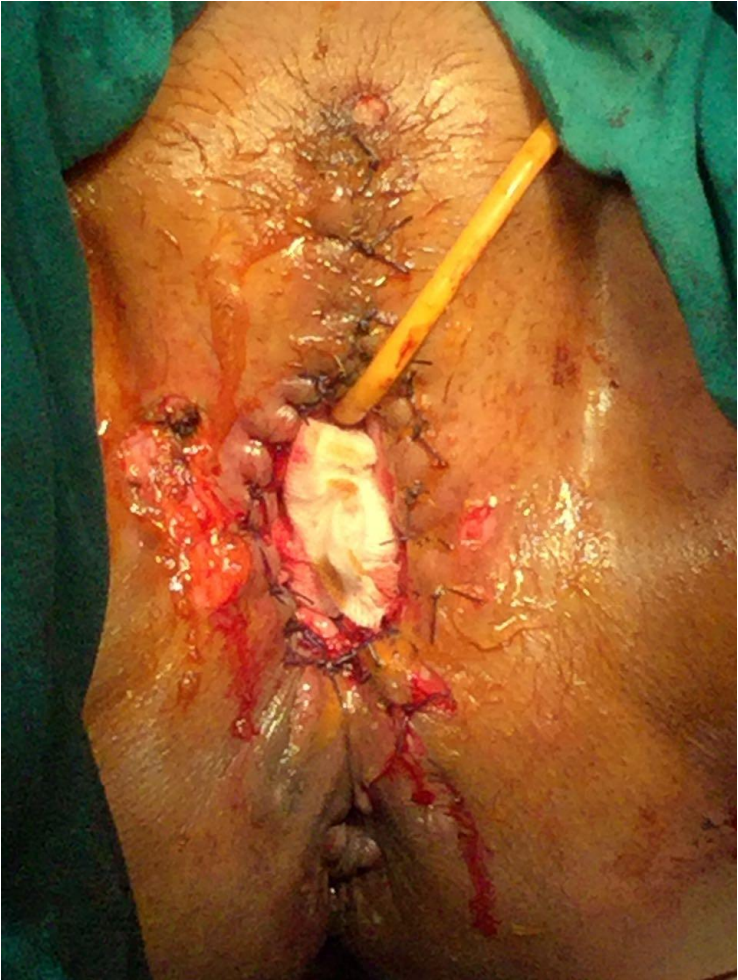
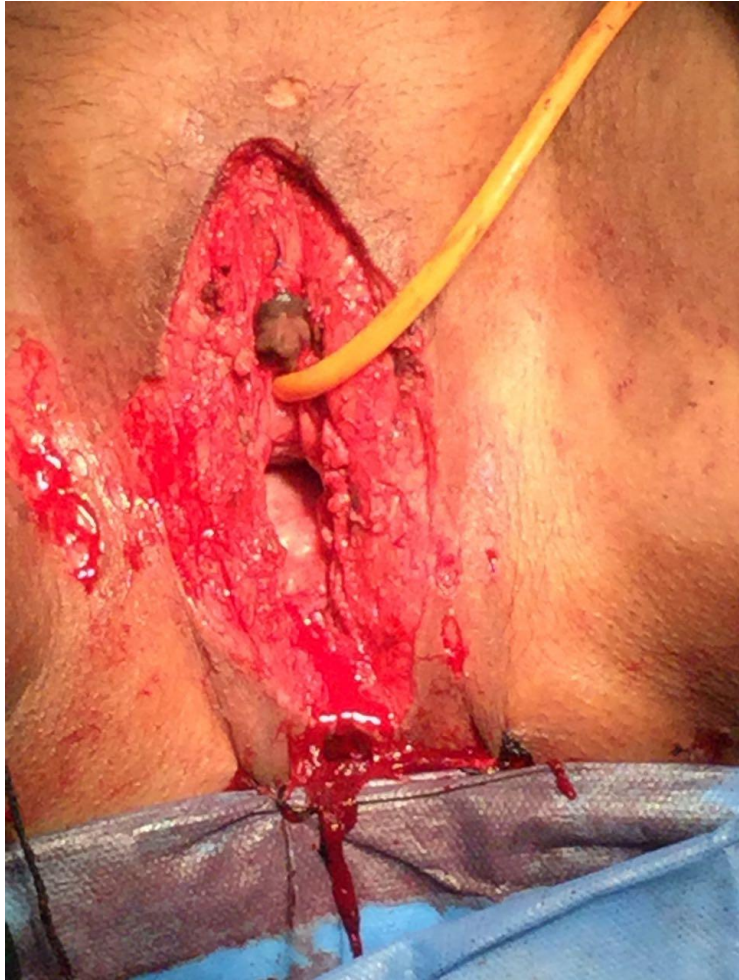
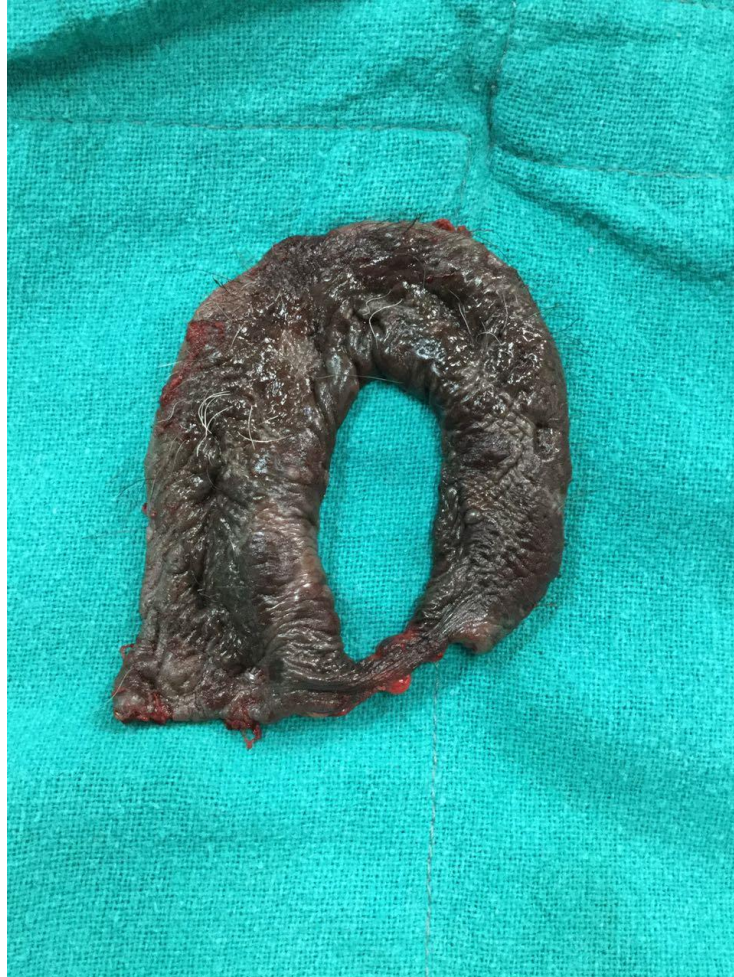CASE 4 -dVIN



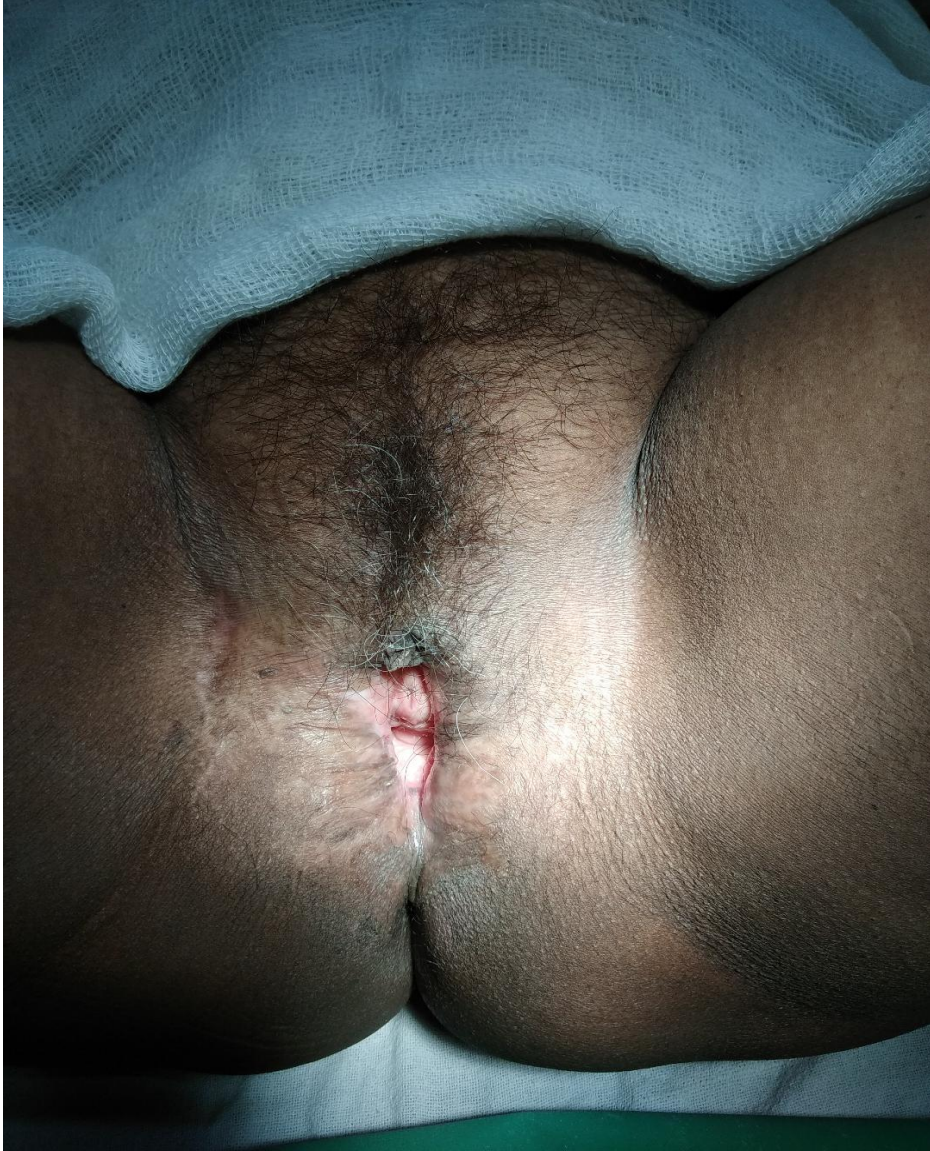- Mrs X, 56 yrs, P3
- K/c/o/ LS for 2 yrs
- Pap smear - HSIL
- Colpo- T2 TZ, no obvious lesion
- Vulvar Bx- VIN III
- Plan-Conisation and skinning vulvectomy

Skinning vulvectomy





- VIN 3
- Left satellite area shows superficial invasion less 0.5 mm
- Cervical cone - normal

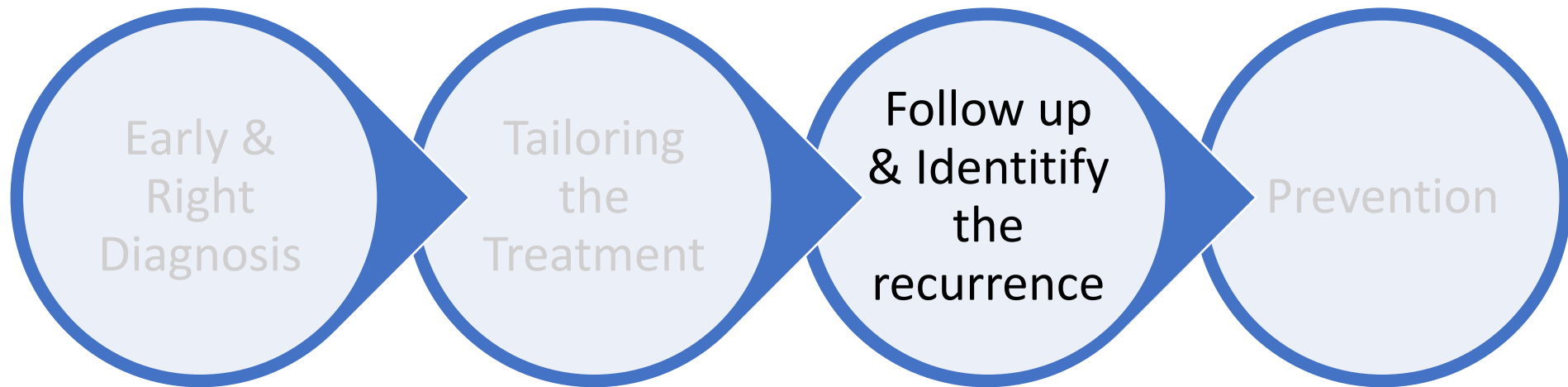


- PET CT whole body - normal
- Lymph node biopsy - normal no malignancy
- Recurrent itching n lesions on clitoris with vulvar lesion 21.10.19
- 4 Bx sent from satellite lesions,
 - fibrosis n sclerosis
 - Clitoral lesion – VIN
- DILEMMA –WHAT NEXT?
- 2021- Bx normal
- Normal vulvoscopies till date
- Always keep underlying dermatosis suppressed with steroids to decrease recurrence

Positive Margins

- Risk of recurrence with negative margins: ~ 20%
- Risk of recurrence with positive margins: ~ 40%
 - Even with positive margins, less than half recur
- closely follow up if there is no carcinoma or visible residual disease
- If recurrence occurs, can re-excise, laser, or topically medicate depending on disease location, # of lesions, and concern for carcinoma

Vulvar Intraepithelial Neoplasia -Optimising The Outcome



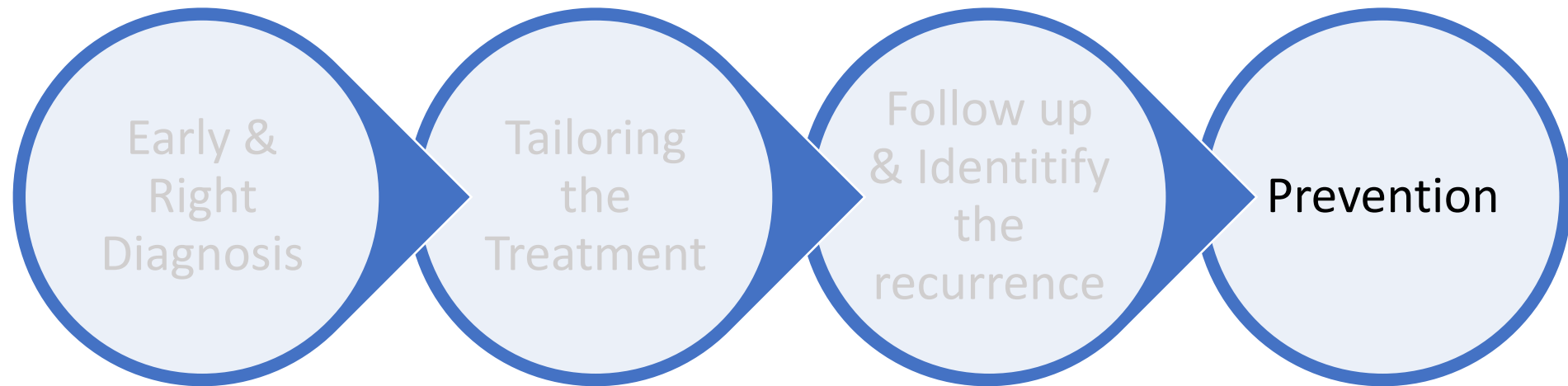
Recurrences

- 20-50% regardless of treating modality
- Risk factors
 - Age >50 years
 - widespread lesions
 - positive margins
 - multifocal lesion,
 - Metasynchronous VAIN/CIN
 - Adjacent LS
 - immunosuppression
 - smoking

FOLLOW UP

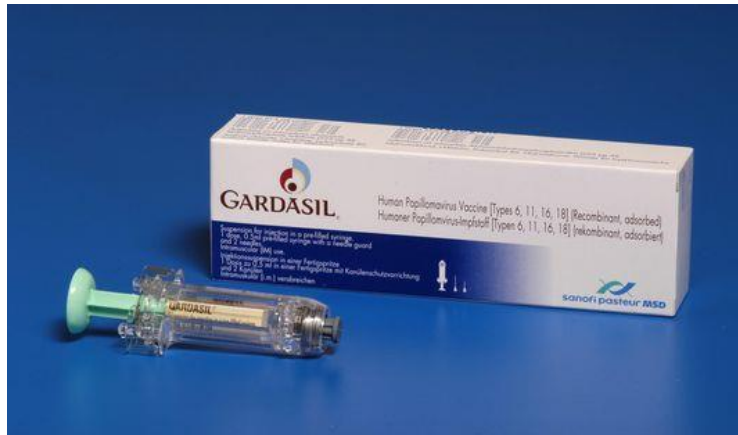- 3 - 6 mths x 2 years
- Annual life long

Vulvar Intraepithelial Neoplasia -Optimizing The Outcome



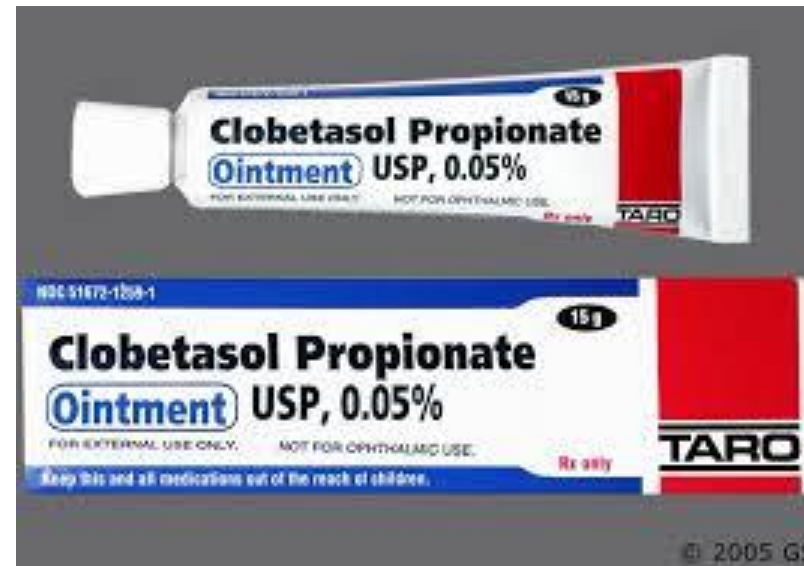Prevention

HSIL- uVIN



Cervavac or Gardasil 9
6,11,16,18 HPV types
+
31,33,45,52,58

VIN Differentiated



Food for Thought

- Give HPV vaccination in VHSIL after treatment to decrease recurrence
??? Till what age
- Therapeutic vaccine – Phase 2 trials have shown promising results

Thank You