

# HPV-independent endocervical adenocarcinoma

**Jun-Hyeong Seo**

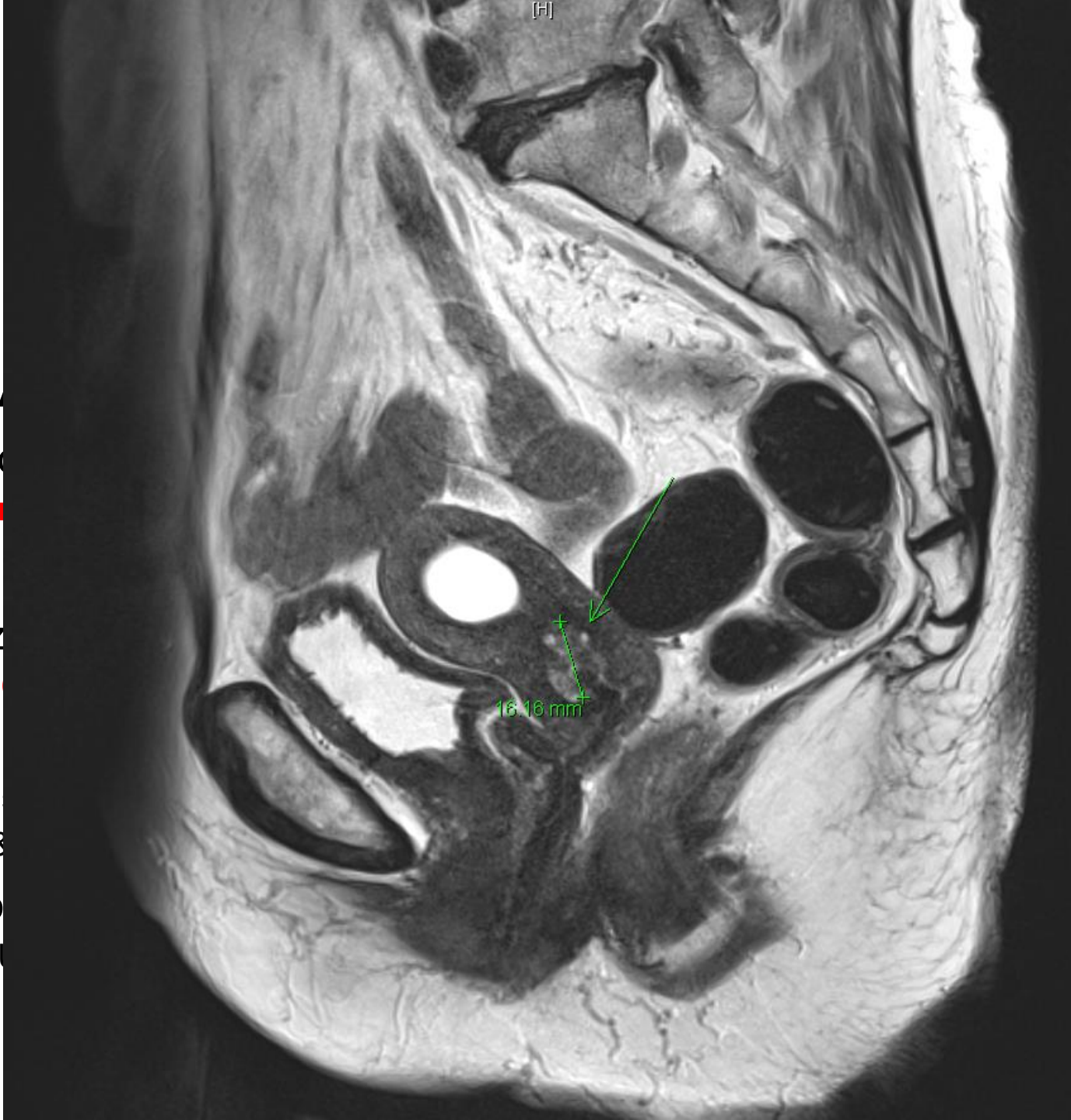Clinical Fellow, Division of Gynecologic Oncology

Department of Obstetrics and Gynecology

Samsung Medical Center

# Case1

- F/73
- 2022-03 Pap: A
- 2022-04 Cervic
  - **Atypical glan**
- 2022-05 Coniz
  - **ADENOCAR**
- 2022-06 Imagi
  - 1.4 cm multi-
  - Parametrial &
- 2022-06 Tumo
  - CA-125: 4.4 U



ic lymphadenectomy  
radiation

**endet**

positive

# Case1

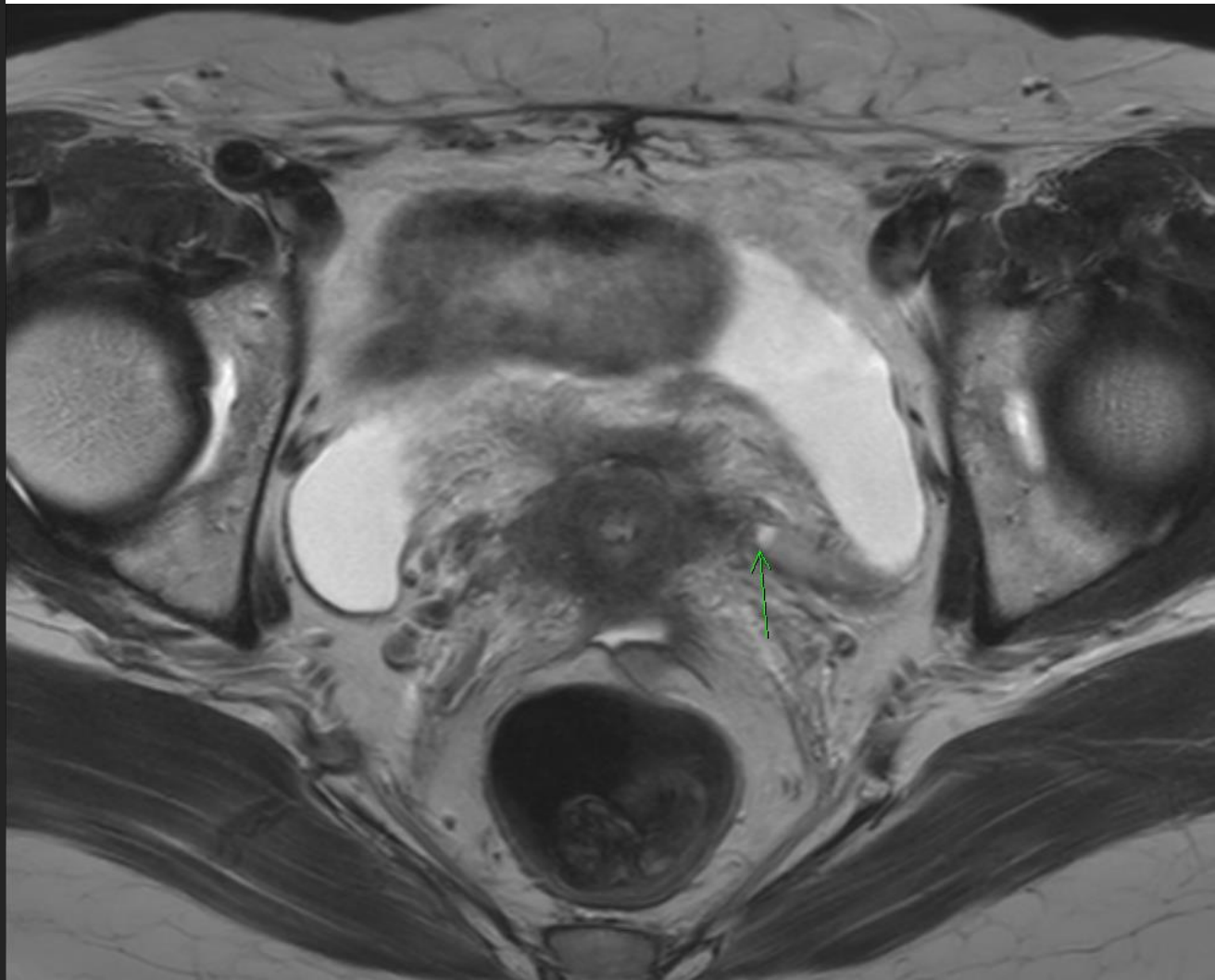
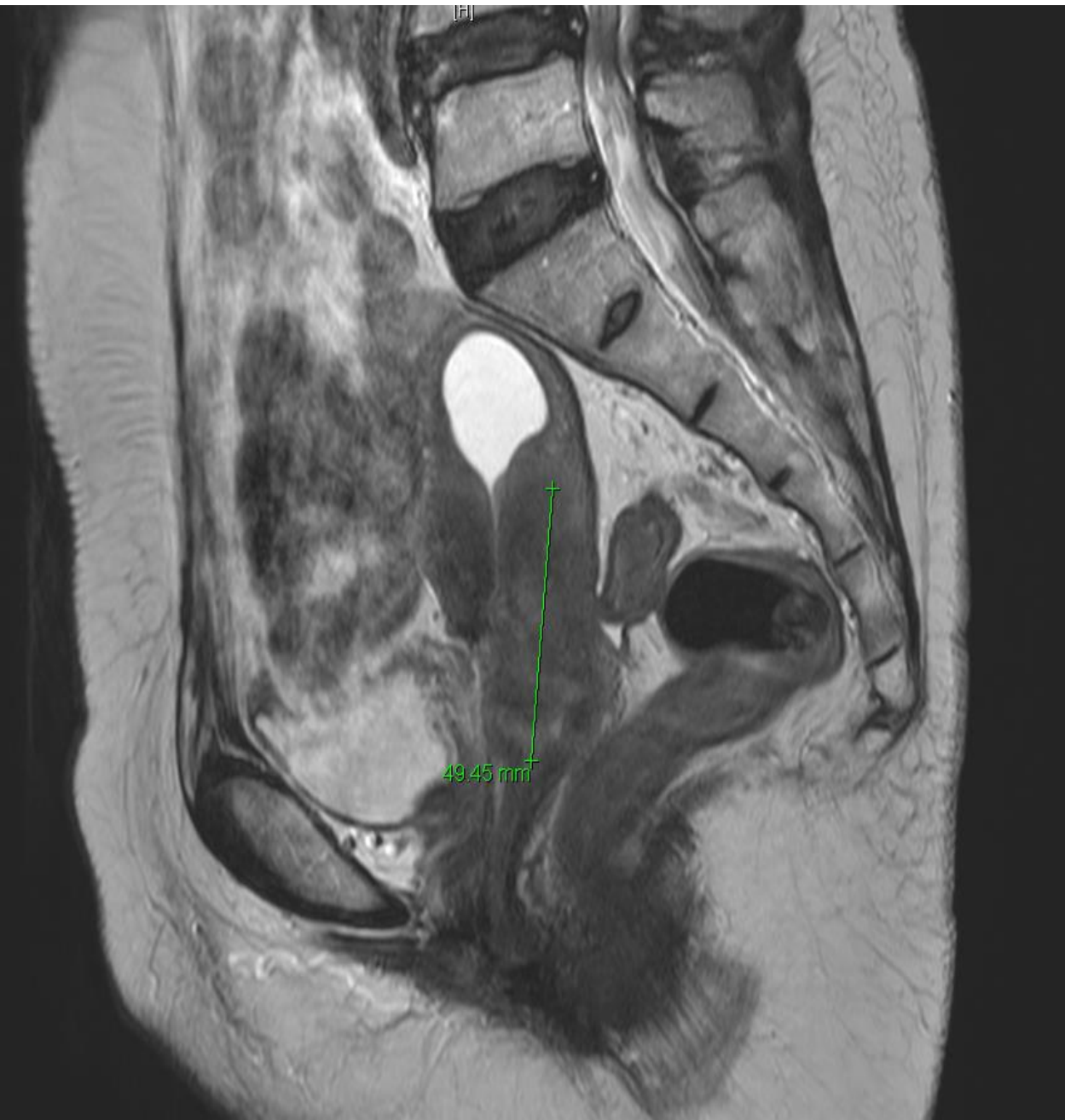- 2022-07 RAH c BSO c PLND

**Adenocarcinoma, HPV-independent (gastric type), cervix**

- + Greatest dimension: **20 mm**
- + Invasion depth: **3 mm** / 12 mm (less than half)
- + Silva system (for adenocarcinoma): Pattern C
- + Lymphovascular invasion: **Absent**
- + Endomyometrial extension: **PRESENT**
- + Serosal extension: Absent
- + Parametrial extension: **Absent** (resection margin: Absent)
- + Vaginal extension: **Absent** (resection margin: Absent; distance: 1.5 cm)
  
- + Lymph node metastasis: Absent (0/26)
  - Left pelvic (0/13)
  - Right pelvic (0/13)

## Q2. Adjuvant treatment?

1. Observation
2. Pelvic EBRT + concurrent platinum-containing chemotherapy + brachytherapy
3. Extended-field EBRT + concurrent platinum-containing chemotherapy + brachytherapy
4. Systemic chemotherapy



# Case2

- 2020-08 Double-J catheter insertion (Left)
- 2020-08 ~ 2020-10 Definite concurrent chemoradiotherapy
  - RT to Whole pelvis, 45Gy/25frs, 3D-CRT
  - Bladder filling, MLB 50.4Gy/28frs + ICR 25Gy/5frs + VMAT right pelvic LN boost 63Gy/35frs
  - Weekly-Cisplatin #1 ~ #6 (40mg/m<sup>2</sup>)
- ~2023.06 No recurrence